

## Percutaneous Interstitial Brachytherapy (IBT) as the Preferred Modality for Liver Tumors in Resource Limited Oncology Departments

Gokula Kumar Appalanaido<sup>1</sup>, Syadwa Abdul Shukor<sup>2</sup>, Muhamad Zabidi Ahmad<sup>1</sup>

<sup>1</sup>Advanced Medical and Dental Institute, Universiti Sains Malaysia, Bertam, 13200 Kepala Batas, Penang

<sup>2</sup>Department of Radiation Oncology, National University Cancer Institute Singapore, National University Hospital, Singapore 119228, Singapore

Dear Editor,

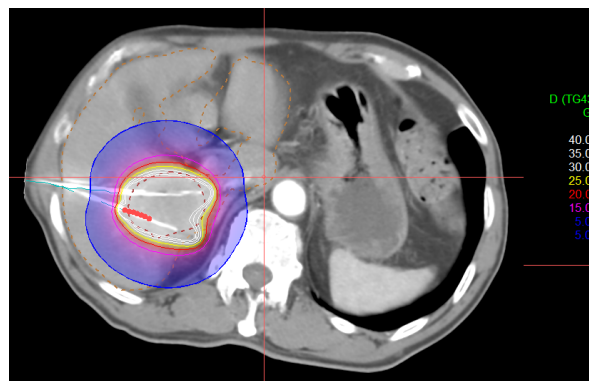
The use of high dose rate interstitial brachytherapy (HDRIBT) is usually limited to gynaecological cancers in the Asia Pacific region. Despite the availability of facility, only a few centres perform HDRIBT to other anatomical sites such as prostate, head and neck, oesophagus, lung and liver. Recent European Society for Medical Oncology (ESMO) guidelines has incorporated HDRIBT as one of the modalities for liver-directed therapy in primary hepatocellular carcinomas (HCC) and colorectal cancer liver metastasis [1, 2]. The literature is still growing on the use of HDRIBT for other metastatic tumors to liver.

Other local ablative therapy to liver such as stereotactic body radiotherapy (SBRT), radiofrequency ablation (RFA) and cryoablation comes with the issue of cost, availability of expertise, anatomical limitation and the need for the multidisciplinary involvement such as the interventional radiologist and anesthetist [3]. The reported local control (LC) rate of HDRIBT liver is equivalent to RFA for metastatic tumors that are <4cm [4]. In contrast to RFA, there is no size limit for the lesion to be treated for HDRIBT if dosimetric constraints of the liver can be achieved [3, 4]. Specifically, HCC is an extremely radiosensitive tumor where a single fraction dose of 15Gy is sufficient to achieve LC and hence reducing the risk of radiation-induced liver disease (RILD) in an already cirrhotic liver [5].

Percutaneous insertion of interstitial brachytherapy applicators and the use of computerized treatment planning system made it possible for virtual adjustment of the lethal radiation dose to cover the tumor edges, unlike RFA where multiple overlapping thermal ablations are needed [3]. There is also no issue with centrally located tumors around the hilum, problem of "heat sink effect" and subdiaphragmatic tumors as in RFA [3]. With the use of flexible plastic applicators, most lesions in

applicators in-situ move with breathing.

HDRIBT liver is a simple and safe procedure that can be performed under percutaneous local anesthesia and minimal sedation with ultrasonography or CT-scan guidance that is readily available in most radiotherapy departments. At Universiti Sains Malaysia (USM), we have successfully performed 112 HDRIBT for liver lesions since November 2018. Figure 1 shows an example of HDRIBT plan for metastatic lesion performed at USM. Though our data is yet to be published, there were no major procedure related toxicity with only 2 patients having CTCAE grade 3 toxicity needing blood transfusion for subcapsular bleeding and no treatment related deaths. From the preliminary assessment, the LC rate in our centre conforms to other published series in the literature [4, 5].



**Figure 1.** Axial CT-image of liver brachytherapy for metastatic lesion of colorectal carcinoma to segment V of liver

Since brachytherapy facility is readily available in most radiotherapy departments, serious consideration should be given for HDRIBT as the preferred choice for liver directed therapy. With moderate training in procedural skills and initial

mentoring from interventional radiologist on the safe percutaneous puncture techniques coupled with the core knowledge of the radiation oncologist, liver HDRIBT program can be implemented with ease in radiotherapy departments. Bearing in mind that single use plastic applicators are less pricy than RFA probes, the overall treatment cost can be lower if existing brachytherapy facility and human resource is used.

#### DECLARATION OF COMPETING INTEREST

Authors declare no conflict of interest in writing this letter to editor.

#### REFERENCES

- [1] Van Cutsem E, Cervantes A, Adam R, Sobrero A, Van Krieken JH, Aderka D, et al. ESMO consensus guidelines for the management of patients with

- metastatic colorectal cancer. *Ann Oncol.* 2016;27(8):1386-422.
- [2] Vogel A, Cervantes A, Chau I, Daniele B, Llovet JM, Meyer T, et al. Hepatocellular carcinoma: ESMO Clinical Practice Guidelines for diagnosis, treatment and follow-up. *Ann Oncol.* 2019;30(5):871-3.
- [3] Wu M-C, Tang Z-Y, Ye S-L, Fan J, Qin S-K, Yang J-M, et al. Expert consensus on local ablation therapies for primary liver cancer. *Chinese Clinical Oncology.* 2012;1(1):14.
- [4] Colletini F, Lutter A, Schnapauff D, Hildebrandt B, Puhl G, Denecke T, et al. Unresectable colorectal liver metastases: percutaneous ablation using CT-guided high-dose-rate brachytherapy (CT-HDBRT). *Rofo.* 2014;186(6):606-12.
- [5] Mohnike K, Wieners G, Schwartz F, Seidensticker M, Pech M, Ruehl R, et al. Computed tomography-guided high-dose-rate brachytherapy in hepatocellular carcinoma: safety, efficacy, and effect on survival. *Int J Radiat Oncol Biol Phys.* 2010;78(1):172-9.